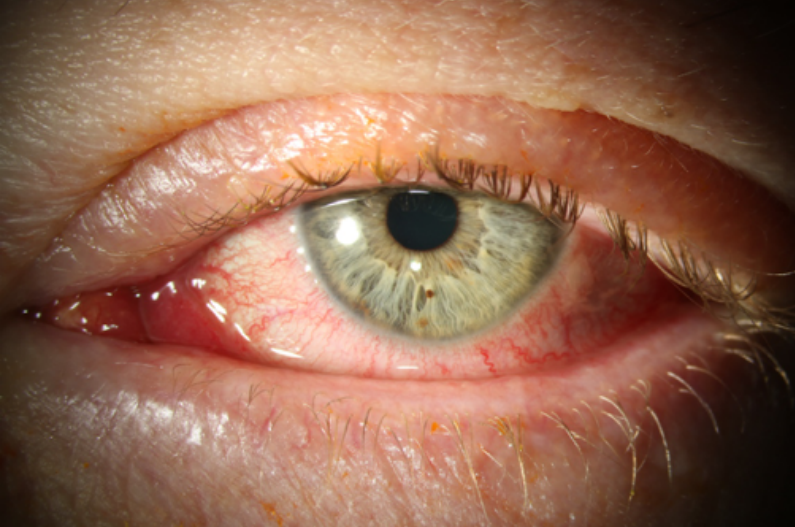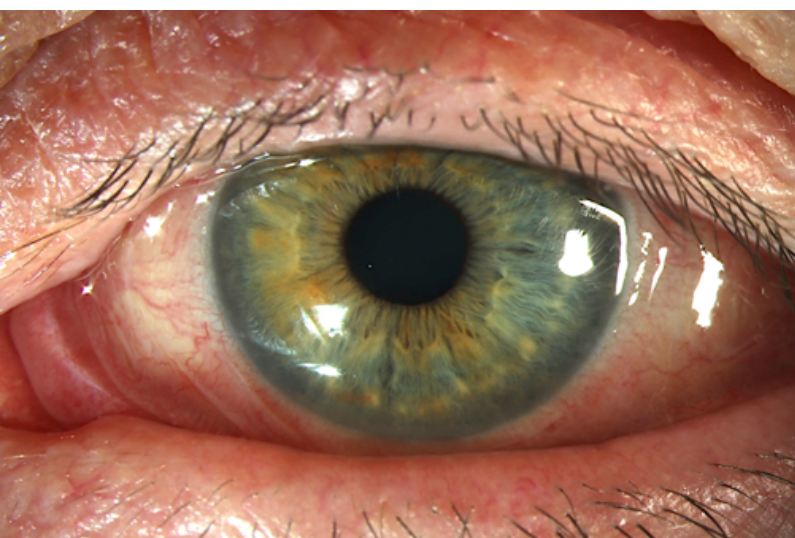
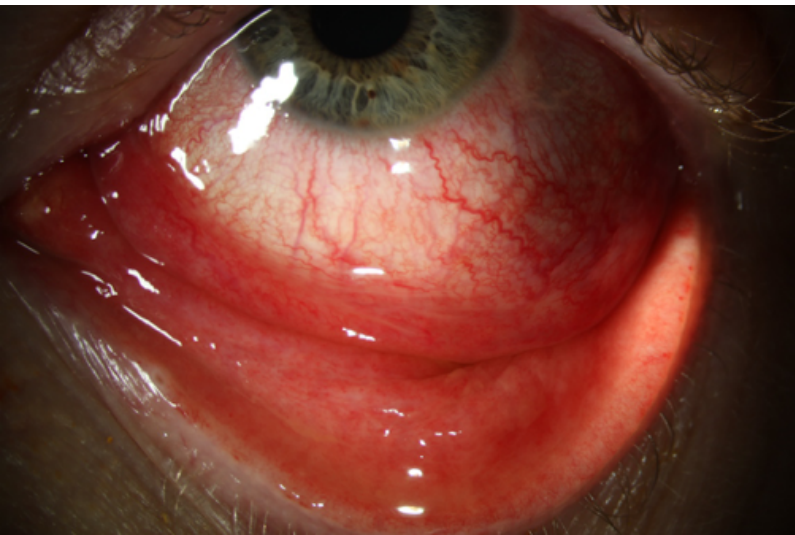


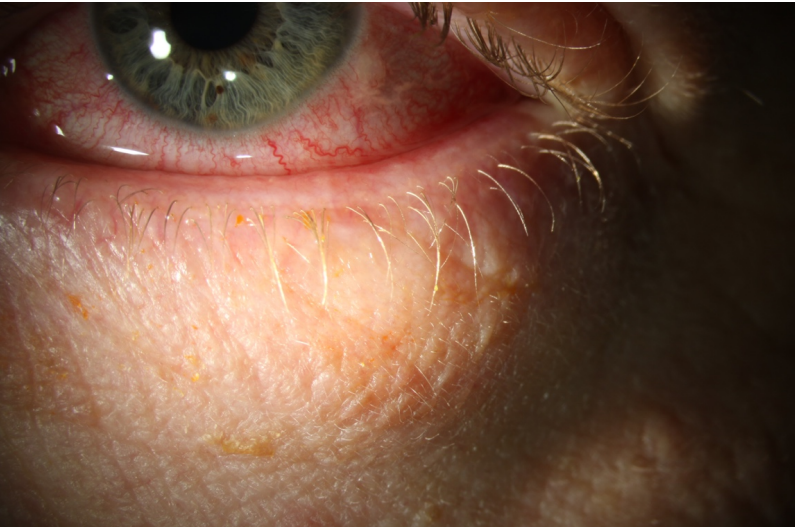
This picture shows the classic redness of conjunctivitis. The eye lashes are clumped together on the upper lid. The eyelids are swollen.



This picture shows the red eye of conjunctivitis. The eye is watering and the conjunctiva is swollen and raised (conjunctival chemosis) on the temporal side.



This picture shows the classic redness of conjunctivitis. The redness extends to the conjunctiva on the inside of the eyelid and looks swollen.



This picture shows the puffiness of the lower eye lid caused by lid oedema.