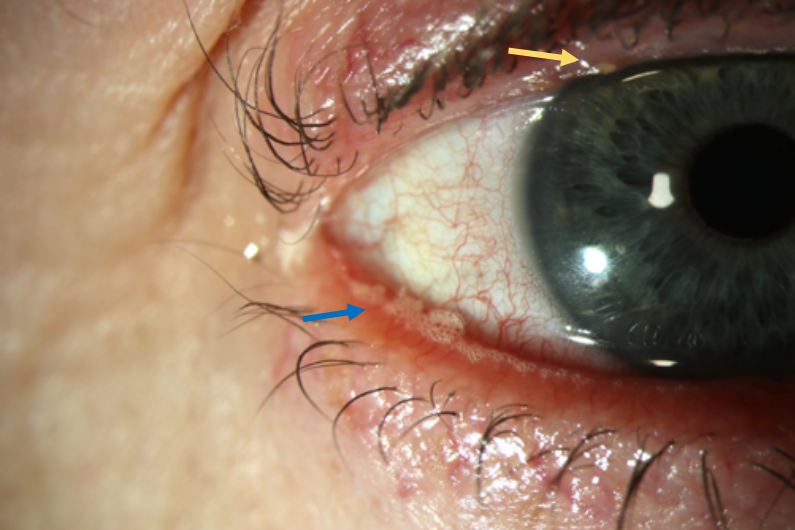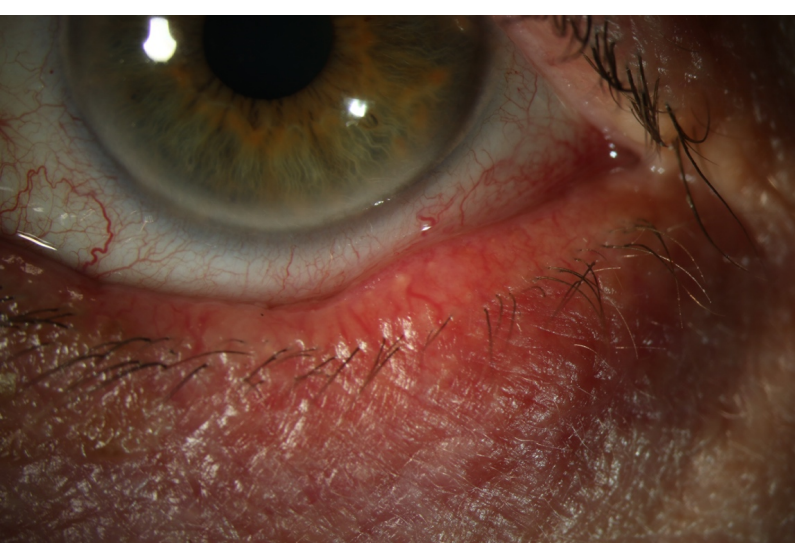

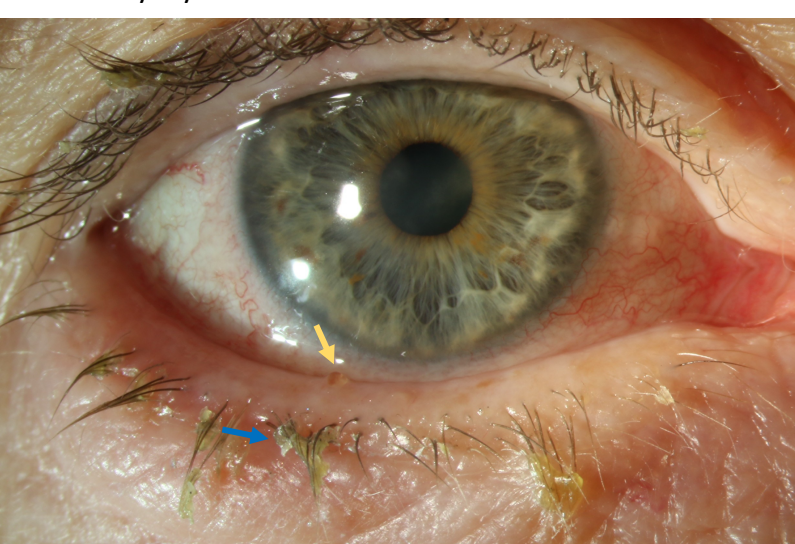
This picture shows the classic thickened red eyelid margins seen in blepharitis. There is also biofilm foam on the margin of the lid (blue arrow). The upper lid also has a small blocked meibomian gland (yellow arrow)



This picture shows again the classic thickened red eyelid margins seen in blepharitis. There is some telangiectasia. There is a blocked meibomian gland which is pointing, this is an early stye.



This picture shows blepharitis, the yellow arrow shows a blocked meibomian gland. The blue arrow shows crusting and debris on the lower eyelid lashes