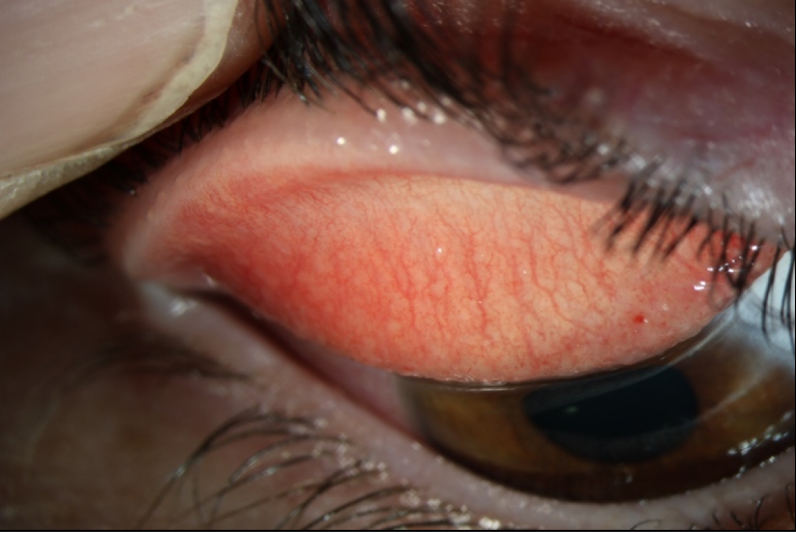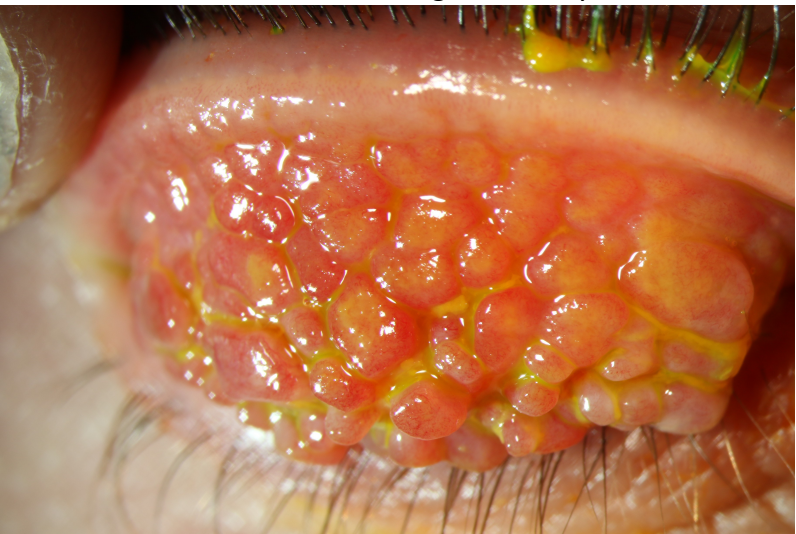




Often there are few clinical signs this photo shows inflammation on the inside of the upper eyelid with papillae (which is a bumpiness of the inside of the eyelid). There is also a small haemorrhage on the eyelid.



This is particularly severe allergic eye disease and would definitely require referral and topical steroids. These are giant papillae.