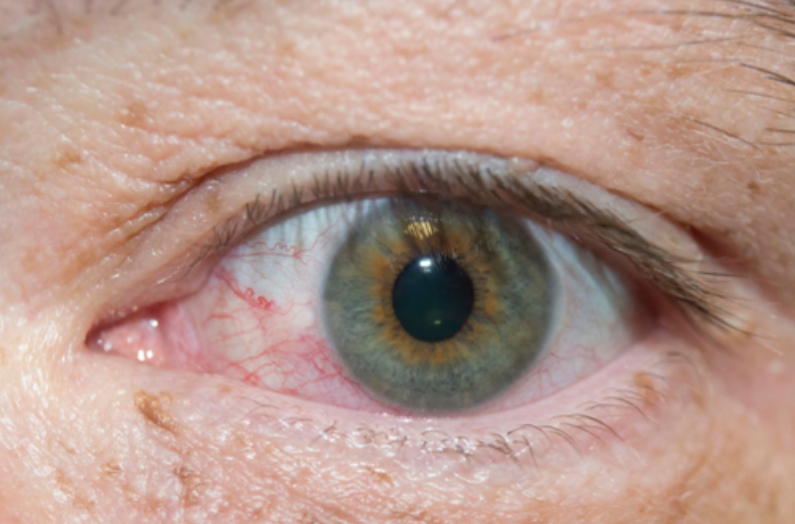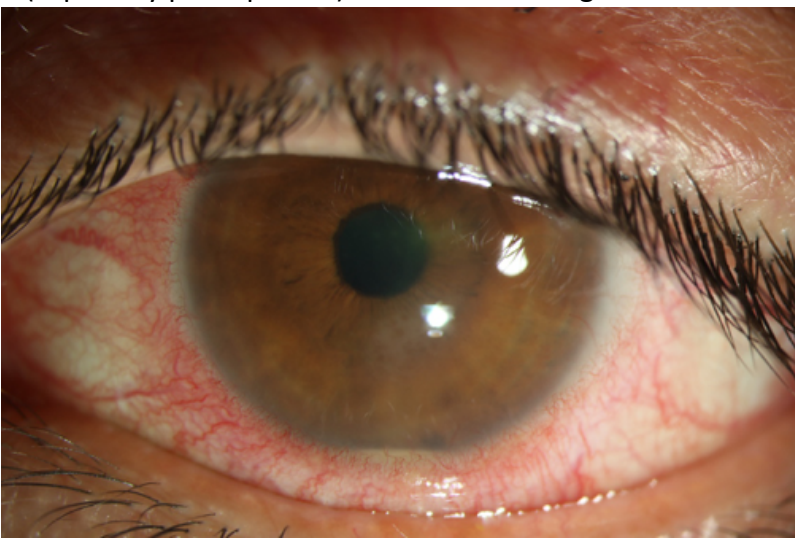
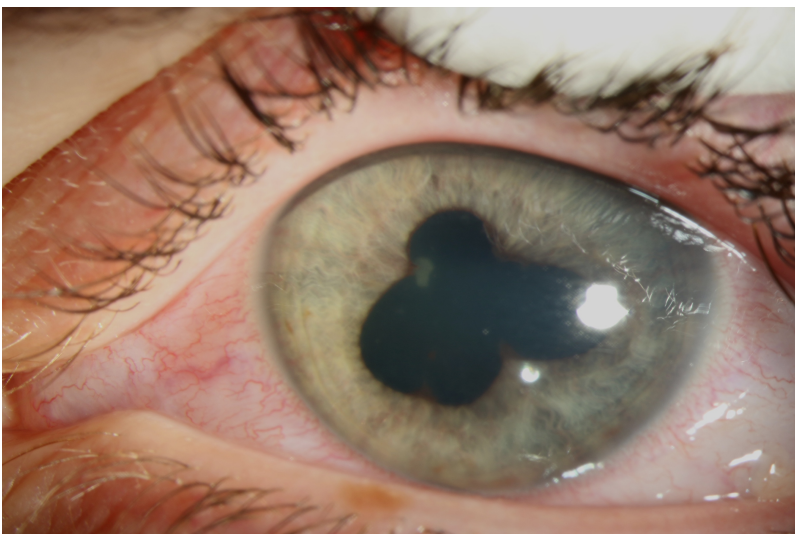


Iritis may cause a mild red eye and the symptoms (especially photophobia) are critical for diagnosis.



Alternatively, the red eye can be pronounced. The key thing to notice in this picture is a small line at the bottom of the iris this is a hypopyon and is a very significant finding and should prompt immediate referral.



Often there is a misshapen pupil. This photo was taken once dilating drops had been applied. A misshapen pupil can be better detected in dim illumination or by looking for a slight difference between pupil sizes.